P0831

Residual periopathogens after access flap and two different antibiotic therapies: 1 year clinical results

D. Axelrad[1], F. Bröseler[2], C. Tietmann[2], S. Jepsen[1], P.-M. Jervøe-Storm[1]
[1] Department of Periodontology, Operative and Preventive Dentistry, University of Bonn, Germany
[2] Private Practice for Periodontology, Aachen, Germany

OBJECTIVES

The efficacy of adjunctive antibiotic treatment in periodontal surgery has not been sufficiently examined[1].
Re-colonisation by certain bacteria and PD ≥ 5 mm after periodontal therapy may represent risk factors for disease progression[2,3].
The present retrospective study examined associations between presence of periodontopathogenic bacteria and clinical outcomes one year after surgery by the adjunctive use of systemic antimicrobials.

Download available at: www.paro-aachen.de

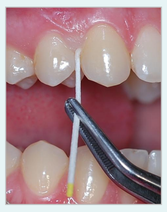

METHODS

56 patients with periodontitis (27 women; mean age: 53±8.5 yrs.) received flap-surgery in combination with antibiotics after oral hygiene-instructions and subgingival scaling and rootplaning. The adjunctive antibiotic therapy followed two different modalities. Either a combination of Amoxicillin and Metronidazole or Ciprofloxacin and Metronidazole (AM group; n = 27) or alternative single antibiotics (other-AB group; n = 29: Metronidazole, Amoxicillin, Doxycyclin, Clindamycin, Ciprofloxacin, Levofloxacin) were prescribed. The prescription was based on microbiological testing and followed the recommendation of van Winkelhoff and Winkel (2005)[4]. All patients were clinically monitored at baseline, before and up to 1 year after surgery. Before and 3 months after surgery subgingival plaque samples were harvested and evaluated by a PCR-based test (micro-Ident®Test, Hain Lifescience GmbH, Germany) for detection of *Aggregatibacter actinomycetemcomitans (Aa), Porphyromonas gingivalis (Pg), Prevotella intermedia (Pi), Tannerella forsythia (Tf) and Treponema denticola (Td) (level of detection:* 10^3 resp. 10^4 copies). Relative amounts of residual pockets ≥ 4mm (RP≥4mm) resp. ≥ 5mm (RP≥5mm) as well as bleeding on probing (BOP) after 1 year were correlated with microbiological findings after 3 months.

RESULTS

Differences from baseline to 1 year showed a significant clinical improvements in both groups (Figure 2 a&b, p<0.000): RP≥4 mm (AM group: 50% (±23) at baseline vs. 8 % (±8) post-operative; other-AB group: 41% (±25)) at baseline vs. 8% (±9) post-op; RP≥5mm (AM group: 28% (±14) vs. 3 % (±4); other-AB group: 20% (±18) vs. 3% (±3)) and BOP (AM group: 72% (±28) at baseline vs. 2% (±3) post-op; other-AB group: 50% (±35) vs. 4% (±6)). There was no significant difference between the groups (p>0.184). Detection frequency of bacteria was decreased in both groups (Figure 3, 4). Significant correlations (Spearman) were found for the other-AB group concerning the amount of RP≥4mm after 1 year and presence of *Pg, Pi* and *Td* after 3 months (p<0.05) as well as concerning the amount of RP≥5mm after 1 year and *Pg, Pi, Tf* and *Td* after 3 months (p<0.03). In the AM group correlations between RP≥4mm resp. RP≥5mm after 1 year and *Td* were found (Table 2, p<0.005).
Preoperatively, no significant correlations were found between target species and clinical parameters. No statistical correlations were found at any time between BOP and the five analyzed bacteria.

Fig.1a: Clinical status at baseline: upper left lateral

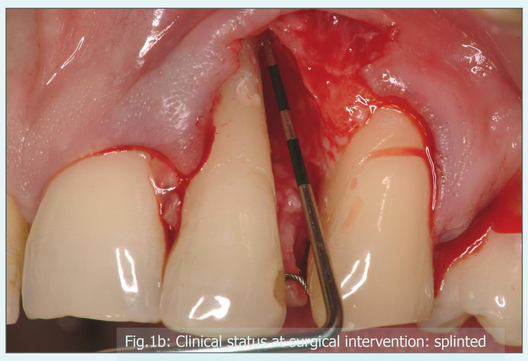
Fig.1b: Clinical status at surgical intervention: splinted

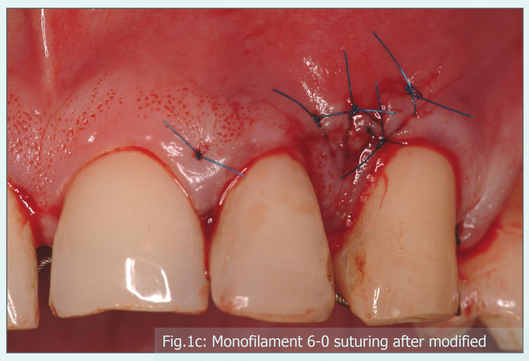
Fig.1c: Monofilament 6-0 suturing after modified

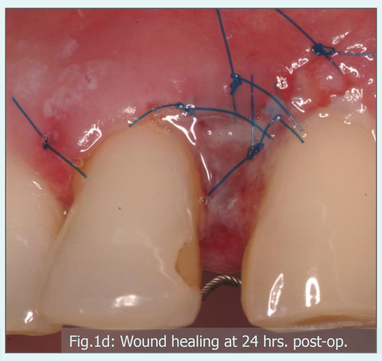
Fig.1d: Wound healing at 24 hrs. post-op.

Fig.1e: Clinical situation at 1 year after flap surgery

	gender		age	smokers
	male	female		
AM (n=27)	16	11	49.8	4
other-AB (n=29)	13	16	49.5	3

Table 1: Demographic data of patients in study groups
AM: Amoxicillin/Metronidazole group
other-AB: Alternative antibiotics group

Bacteria	*Aa*		*Pg*		*Pi*		*Tf*		*Td*	
Category of PD	RP ≥ 4mm	RP ≥ 5mm	RP ≥ 4mm	RP ≥ 5mm	RP ≥ 4mm	RP ≥ 5mm	RP ≥ 4mm	RP ≥ 5mm	RP ≥ 4mm	RP ≥ 5mm
AM (n=27)	ns	ns	ns	ns	ns	ns	ns	ns	0.005	0.003
other-AB (n=29)	ns	ns	0.054	0.026	0.045	0.032	ns	0.025	0.036	0.006

Table 2: *p*-values of correlations (Spearman). Presence of T. denticola as found 3 months after surgery was associated with less favourable clinical outcomes 12 months after surgery (* in both groups)
AM: Amoxicillin/Metronidazole group **other-AB:** Alternative antibiotics group ns: not significant

Fig. 2 a: AM group

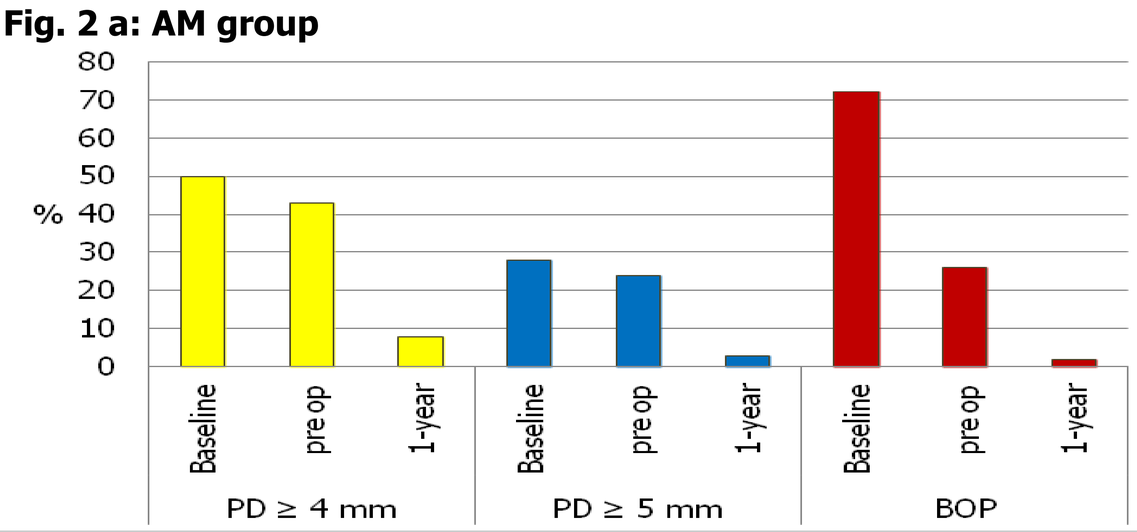

Fig. 2b: other- AB group

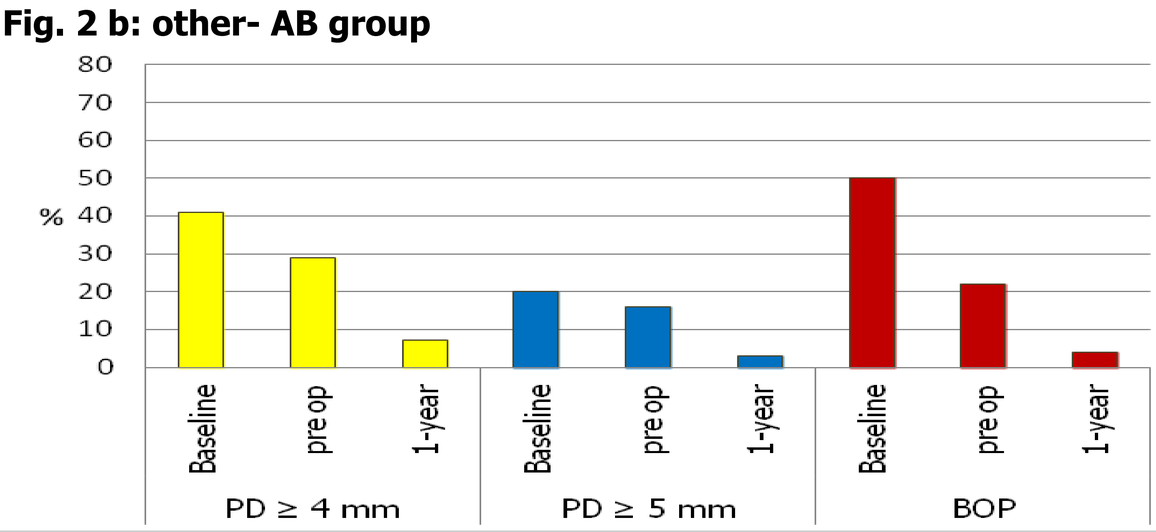

Fig. 2a and 2b: Relative change of clinical parameters during therapy according to the antibiotical treatment (mean-value)

Fig. 3

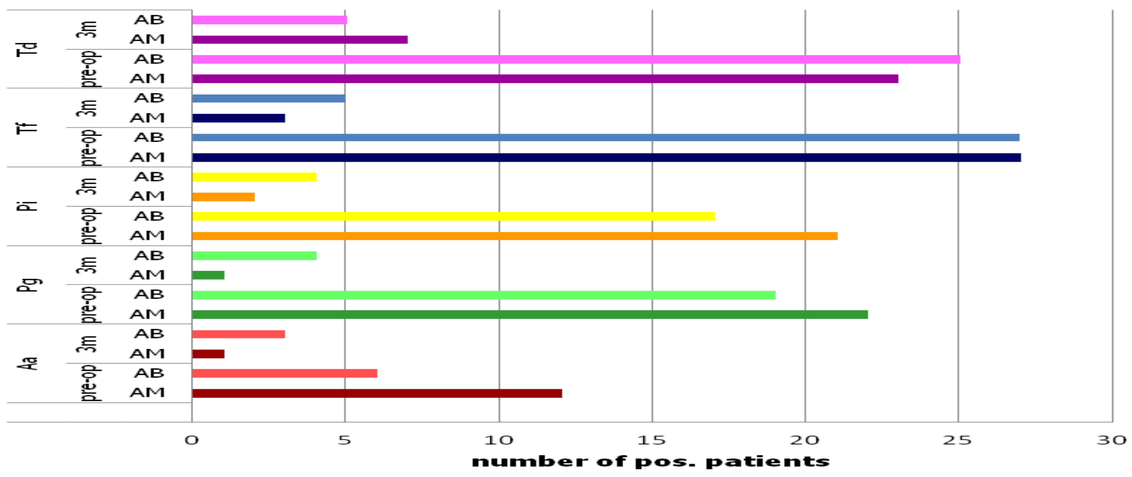

Fig. 3: Detection frequency of the five target bacteria

Fig. 4



Fig. 4: Detection frequency of target bacteria in subgingival plaque samples before surgery compared to 3 months after surgery, each score representing one positive pooled sample. Score 3 – 7 indicate the order of bacterial counts. The data are not linked to any specific site:
3 indicating a range ≥ 10^3 but < 10^4 bacteria / plaque sample, 4 indicating a range ≥ 10^4 but < 10^5 bacteria / plaque sample,
5 indicating a range ≥ 10^5 but < 10^6 bacteria / plaque sample, 6 indicating a range ≥ 10^6 but < 10^7 bacteria / plaque sample and
7 indicating a range ≥ 10^7 bacteria / plaque sample (data presentation adapted from Mombelli et al. 1995)[5]

CONCLUSION

The results of the present study indicate similar clinical and microbiological outcomes following different antibiotic therapy modalities.
Residual bacteria after flap surgery + antibiotics were correlated with a less favourable clinical outcome.

ZAHNÄRZTLICHE PRAXIS FÜR PARODONTOLOGIE
Dr. med. dent. FRANK BRÖSELER
Dr. med. dent. CHRISTINA TIETMANN
Aachen, Germany | www.paro-aachen.de

REFERENCES
1: Herrera et al. (2008), *Journal of Clinical Periodontology* 35, 45-66
2: Teles et al. (2006), *Periodontology 2000*, 42, 180-218
3: Matuliene et al. (2008), *Journal of Clinical Periodontology* 35, 685-695
4: van Winkelhoff and Winkel (2005), *Periodontology 2000*, 39, 40-52
5: Mombelli et al. (1995) *Journal of Clinical Periodontology* 22, 124-130
6: Clinical Photographs: Dr. C. Tietmann, Aachen
7: Surgery (all documented cases): Dr. F. Bröseler & Dr. C. Tietmann, Aachen

DINAH AXELRAD
Department of Periodontology, Operative and Preventive Dentistry, University of Bonn
Welschnonnenstr. 17, 53111 Bonn
Email: dinah-axelrad@web.de

universitätbonn